



## Optic neuritis in a teenage girl with granulomatosis with polyangiitis

### Optički neuritis kod tinejdžerke sa granulomatozom sa poliangiitismom

Dejan Bokonić\*, Nada Avram\*, Predrag Minić†‡, Aleksandra Radosavljević‡§

University of East Sarajevo, \*Faculty of Medicine, Foča, Republic of Srpska, Bosnia and Herzegovina; †Mother and Child Health Care Institute of Serbia “Dr. Vukan Čupić“, Belgrade, Serbia; ‡Faculty of Medicine, Belgrade, Serbia; §Clinical Centre of Serbia, §Clinic for Eye Diseases, Belgrade, Serbia

#### Abstract

**Introduction.** Granulomatosis with polyangiitis (GPA), formerly known as Wegener’s granulomatosis, is characterized by necrotizing granulomatous inflammation in various tissues, including blood vessels, but primarily in the respiratory tract and kidneys. Clinical manifestations can be diverse, including inflammation of the eye and adnexa. Optic neuritis is a very rare ophthalmological manifestation of GPA, not previously described in a teenager. **Case report.** We presented a case of a 16-year-old girl with a rare extrapulmonary manifestation of GPA. The girl had a previous history of GPA and complained of a sudden blurred vision in the left eye. She was promptly referred to an ophthalmologist who noted a decreased visual acuity of 20/400 in the left eye. Colour vision was impaired in the spectrum of red colour. Clinical examination revealed normal anterior segment findings. On ophthalmoscopy, the left optic nerve oedema was noted. Urgent computed tomography of the left orbit showed a soft tissue mass around the optic nerve in the apex of the orbit. Magnetic resonance imaging confirmed the diagnosis of optic perineuritis. After pulse doses of methylprednisolone, the girl achieved complete resolution of vision in the left eye. **Conclusion.** If untreated, inflammation of the optic nerve can lead to a permanent loss of vision. Prompt diagnostic and adequate treatment of patients with GPA is needed in order to prevent vision-threatening complications and control the systemic disease.

#### Key words:

diagnosis; optic nerve; optic neuritis; treatment outcome; wegenger granulomatosis.

#### Apstrakt

**Uvod.** Granulomatoza sa poliangiitismom (GPA), ranije poznata kao Wegenerova granulomatoza, karakteriše se nekrotizujućom granulomatoznom inflamacijom u različitim tkivima, uključujući krvne sudove, ali primarno unutar respiratornog trakta i bubrega. Kliničke manifestacije mogu biti raznovrsne uključujući i zapaljenje oka i adneksa. Optički neuritis je veoma retka oftalmološka manifestacija GPA, koja do sada nije opisana kod mladih osoba. **Prikaz bolesnika.** Prikazana je 16-godišnja devojčica sa retkom ekstrapulmonalnom manifestacijom GPA. Bolesnica, ranije lečena zbog GPA, požalila se na iznenadni pad vida na levom oku. Hitno je upućena oftalmologu koji je ustanovio smanjenu vidnu oštrinu levog oka 3/60. Kolorni vid je bio oštećen u spektru crvene boje. Kliničkim pregledom utvrđen je normalan nalaz na prednjem segmentu oka. Pregledom očnog dna uočen je edem vidnog živca levo. Kompjuterizovana tomografija leve orbite otkrila je mekotivnu masu oko optikusa u vrhu orbite. Magnetnom rezonancom mozga potvrđena je dijagnoza optičkog perineuritisa. Posle pulsnihi doza metilprednizolona došlo je do potpunog oporavka funkcije vida levog oka. **Zaključak.** Ukoliko se zapaljenje optikusa ne leči, može dovesti do trajnog gubitka vida. Stoga je neophodno hitno sprovesti kompletnu dijagnostiku i adekvatno lečenje obolelih od GPA, kako bi se sprečile komplikacije koje mogu ugroziti vid i kontrolisala sistemska bolest.

#### Ključne reči:

dijagnoza; optički nerv, neuritis; lečenje; ishod; wegengerova granulomatoza.

#### Introduction

Granulomatosis with polyangiitis (GPA) is a systemic inflammatory disease of unknown aetiology. Its main clinical features include the formation of granulomas, vasculitis of

the upper and lower respiratory tract, glomerulonephritis, and tissue necrosis <sup>1</sup>. Pathophysiology of granulomas is complex. It includes the destruction of normal tissue, a variable degree of obstruction of small and medium-sized blood vessels, and reduction of the amount of blood that

reaches different tissues and organs<sup>2</sup>. The disease can be manifested at all ages, but most often around 40 years of age. It is rare in the children population<sup>3,4</sup>. The incidence of GPA is 3 cases per 100,000 people.

One of the first signs of the disease is inflammation of the airways. Lung nodules usually cause symptoms of pneumonia with rapid breathing, cough, and chest pain. Involvement of the kidneys appears only in a small number of patients at the beginning of the disease, but this number increases as the disease progresses. In addition, other systems can be affected, and there are general signs of the disease, such as weight loss, fatigue, fever, night sweats, and joint pain. Occasionally, GPA can start as fulminant form<sup>3</sup>. Inflammation can affect different parts of the eye and manifest with scleritis, ulcerative keratitis, occlusive retinal periarteritis, and uveitis. Regarding the ocular adnexa, nasolacrimal duct obstruction can occur and lead to dacryocystitis, or inflammation can occur in the orbital tissue in the form of orbital pseudotumor<sup>5,6</sup>.

The presence of at least two of the four criteria mentioned above is sufficient for establishing the diagnosis<sup>7</sup>. Antineutrophil cytoplasmic antibodies (cANCA) are autoantibodies directed against serine elastase 3. They are quite important in the pathophysiology of the disease<sup>1,5,8</sup>. On chest radiographs and computed tomography (CT), infiltrates, nodules, and cavities can be usually found. The golden standard for establishing the diagnosis of GPA is the pathohistological confirmation of necrotizing vasculitis, the presence of large areas of necrosis, or granulomatous inflammation in the skin, kidney, or lung biopsy specimens<sup>1</sup>.

The treatment of GPA includes a high dose of corticosteroids for prompt reduction of the inflammation and immunosuppressives, or biologics, in order to achieve long-term remission of the disease<sup>9</sup>. The risk of the disease relapse is very high and almost inevitable without maintenance treatment, but also, despite therapy, a 5-year relapse-free rate is as low as 50%<sup>9</sup>.

### Case report

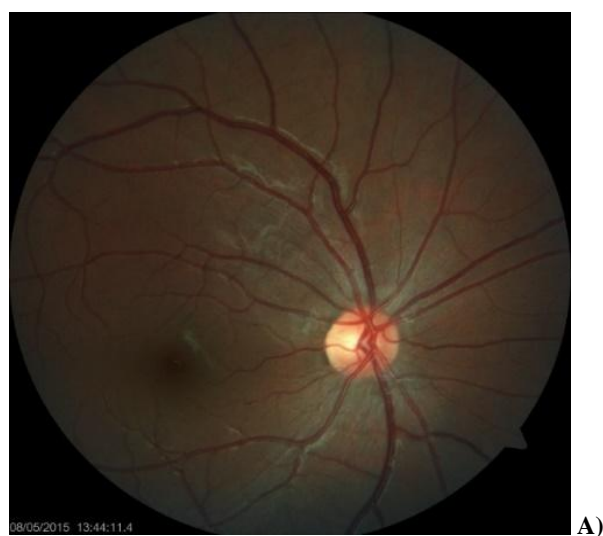We presented a case of a 16-year-old girl who has been complaining of dizziness and blurred vision in her left eye that had started a few days before she went to see a doctor (April 2016). She visited an ophthalmologist for a medical check-up. The ophthalmologist noticed impaired vision and also registered oedema of the optic disc.

The patient was a second child from a third controlled pregnancy, delivered on time, via vaginal delivery, birth body weight 3,100 gr, birth body length: 52 cm, immediately started to cry, not reanimated. She was not allergic, fully vaccinated according to age. She denied inheritable diseases in the family. In her past medical history, the girl was treated under the diagnosis of "granulomatous pulmonary disease" since September 2011, when she underwent left thoracotomy due to the presence of a tumorous mass in her left lung. Biopsy showed granulomatous inflammation in the lung, and a diagnosis of GPA was established. cANCA were positive. Steroid

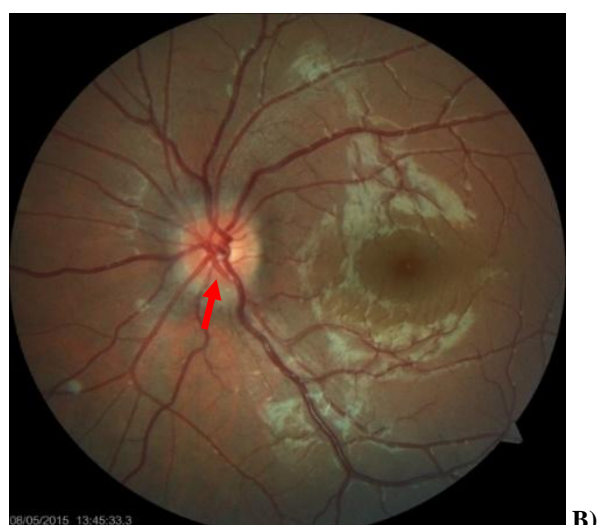therapy was introduced with 30 mg of prednisone per day, which was very slowly tapered to 2.5 mg every other day, with good clinical response at the beginning. After one month, she had a relapse of the disease manifested with nodules in the lungs, which disappeared after the dosage of prednisone was raised. After tapering the dose of steroids for the second time to 2.5 mg every other day, at the end of April 2016, the eye symptoms appeared.

Due to the known underlying disease and the new symptoms reported by the girl, she was admitted to the Pediatric Department for urgent treatment. Upon admission, the 16-year-old girl had body weight 42 kg (50th percentile), body height 146 cm (40th percentile), was conscious, without fever, appeared well hydrated. The pupils symmetrically reacted to light, sclera was white without pathological changes, and conjunctiva was normally vascularised. Her throat was erythematous. During lung auscultation, a normal respiratory sound was noticed, without accompanying whistles and crackles. Cardiac rhythm was normal, tones were clear, murmur was not registered. Respiratory rate was 20 per min, heart rate 88 per min, and blood pressure 100/60 mmHg. The abdomen was neither tender nor distended. The liver and spleen were not palpable. Rough neurological examination showed no abnormalities. Other physical examinations were without pathology. Laboratory findings included: erythrocyte sedimentation rate (ESR), 24/50 mm/h [normal values (nr) 5/15 mm/h]; white blood cells (WBC),  $8.9 \times 10^9/L$  (nr:  $4.5-11.0 \times 10^9$ ); erythrocytes,  $4.59 \times 10^{12}/L$  (nr:  $4-6.5 \times 10^{12}/L$ ); hemoglobin, 12.8 g/dL (nr: 12.0-17.0/g/dL); platelets,  $305 \times 10^9/L$  (nr:  $150-440 \times 10^9/L$ ); serum urea nitrogen, 2.5 mmol/L (nr: 2.8-8.3 mmol/L); serum creatinine (sCr), 46.8  $\mu\text{mol}/L$  (nr: 44-80  $\mu\text{mol}/L$ ); asparatate aminotransferase (AST), 34 U/L (nr: 24-49 U/L); alanine aminotransferase (ALT), 32 U/L (nr: 9-20 U/L); alkaline phosphatase (ALP), 91 U/L (nr: 35-105 U/L); blood sugar, 3.2 mmol/L (nr: 4.1-6.1 mmol/L); 24 h diuresis, 2,210 mL; uoproteins, 0.17 g/24 h; clearance of creatinine (CICr), 153.9 mmol/L/24 h; urine (CICr =  $0.85 \times (140 - \text{age in years})/(\text{sCr}) \times (\text{body weight}/72)$ ); C-reactive protein (CRP), 15 mg/L (nr: 0-6 mg/L); cANCA, 1.6 U/mL (nr: 0-20 U/mL). Urine had a normal appearance.

A complete ophthalmological examination was performed. The best corrected visual acuity (BCVA) was 20/400 in the right and 20/20 in the left eye. In her ophthalmological history, the right eye was amblyopic (previous BCVA was 20/60). The anterior segment of both eyes and the fundus of the right eye had a normal appearance (Figure 1A). Oedema was noted in the left fundus optic disc, with slight elevation, hyperaemia, and unclear boundaries. The funnel of the blood vessels was centrally positioned. Blood vessels had normal calibre. Macula had normal macular reflex (Figure 1B). The initial visual field could not be performed since the patient was treated at the Pediatric Department and was seen by a consultant ophthalmologist.



A)



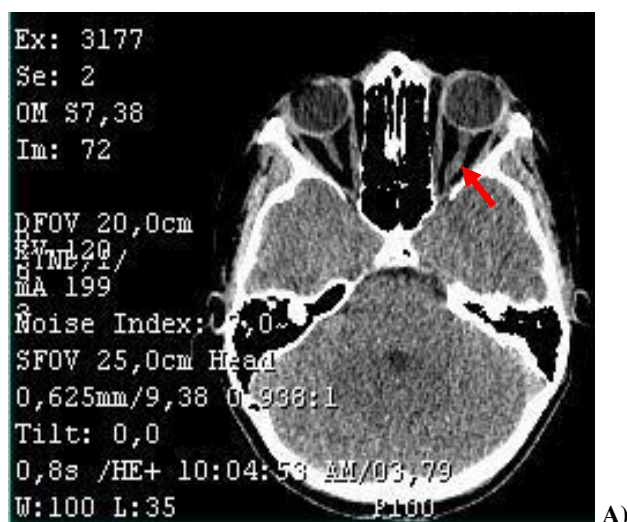
B)

**Fig. 1 – Fundus photo of the right (A) and left eye (B) at presentation, showing normal findings in the right and optic nerve oedema in the left eye (arrow).**

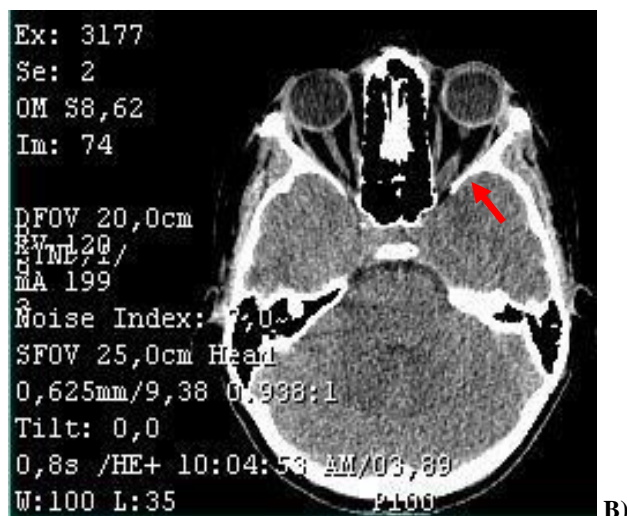
On axial sections and subsequent reconstructions, the CT of the brain and orbits showed that a soft tissue mass was present in the apex of the left orbit, which, according to its size and position, appeared to belong to the thickened and inflamed optic nerve (optic perineuritis). No expansive formations were observed in the right orbit, and the optic nerve was clearly visible. Paranasal sinuses were normally developed and pneumatized, and no abnormal collection or other pathological changes were observed. The nasal septum was centrally positioned. On available sections in the endocranium level, no significant alterations in intensity were observed (Figures 2A and 2B).

Due to unclear delineation of the observed lesion, nuclear magnetic resonance was performed, and previous findings were confirmed.

Ultrasound of the abdomen and radiography of the lungs were also performed to look for the presence of nodules in parenchymal organs. Ultrasound of the abdomen showed that the liver had normal localization, an ordinary



A)

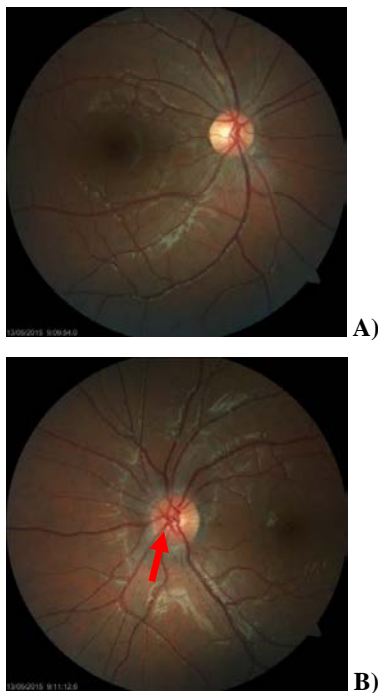

B)

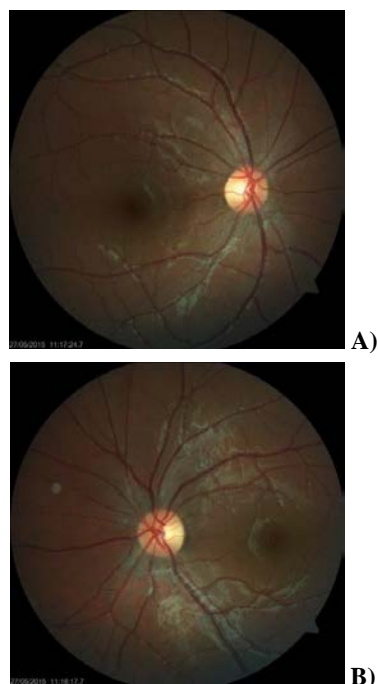
**Fig. 2 – Computed tomography (CT) scan of the brain and orbits shows thickening of the left optic nerve (A) especially in the apex of the orbit (B).**

shape, a diameter of 108 mm, and a homogeneous echo structure. The gallbladder was without pathological changes. The pancreas had a homogeneous structure and proper size. The right kidney had unchanged localization, normal shape, and size (95 x 43 mm), without urine stoppage and with clear corticomedullary boundary. The left kidney had unchanged localization, normal shape, and size (93 x 47 mm), with a clear corticomedullary boundary. Spleen had normal localization, shape, and size (87 x 33 mm). The free liquid in the abdomen was not noticed. Chest radiography showed no pathological changes in the lung parenchyma.

After the patient was admitted to the hospital, pulse doses of methylprednisolone were introduced along with proton pump inhibitors for protection of the gastric mucosa. Blood pressure and blood glucose levels were regularly monitored, and no major changes were noticed. After three days of pulse therapy, visual acuity started to improve. Therapy with steroids (40 mg/day of oral prednisone) was continued for the next ten days. On medical check-up after 5 (Figures 3A and 3B) and 20 days (Figures 4A and 4B),



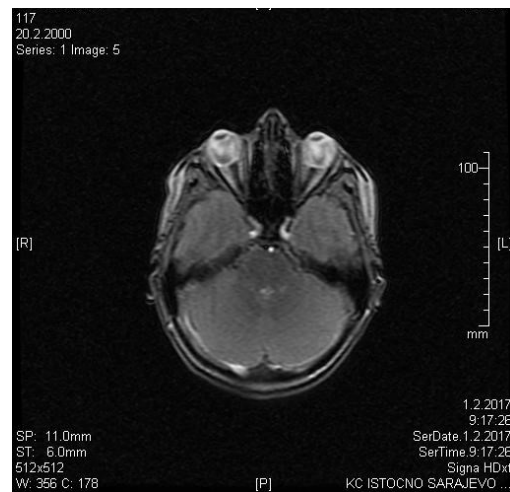
**Fig. 3 – Fundus photo of the right (A) and left eye (B) after 5 days of treatment, with gradual resolution of optic nerve oedema in the left eye (arrow).**



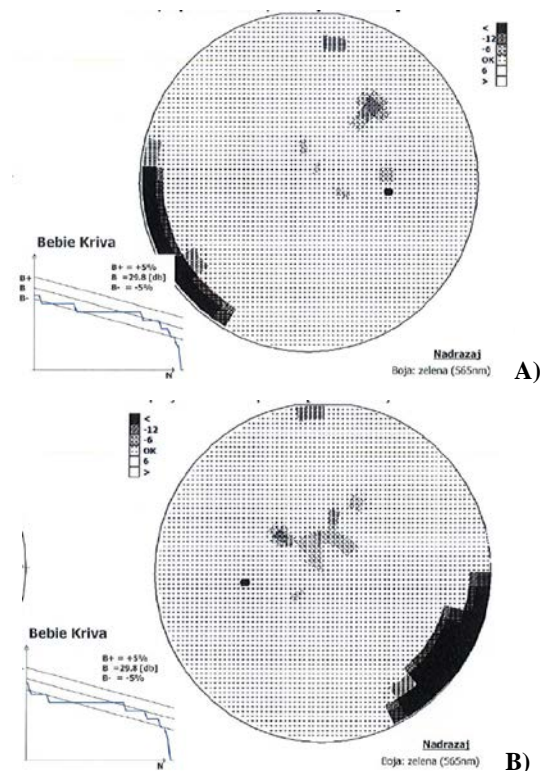
**Fig. 4 – Fundus photo of the right (A) and left eye (B) after 20 days of treatment, showing normal findings.**

oedema of the left optic nerve gradually and completely resolved, thus steroid therapy was slowly tapered. Finally, when the patient reached the dose of 5 mg of prednisone every other day, she was maintained on this dose in order to prevent further relapses. At the end of the treatment, the vision was completely recovered in the left eye except for

minor changes in colour vision. The girl felt well, without any symptoms regarding the respiratory tract or the eyes. Control nuclear magnetic resonance of the brain was performed and confirmed resolution of the lesion (Figure 5). Control visual field showed normal findings in both eyes (Figures 6A and 6B). The patient was followed up for 3 years and had no systemic or ophthalmologic recurrences of GPA.



**Fig. 5 – Control magnetic resonance imaging of the brain after 18 months of follow-up, shows normal thickness of both optic nerves.**



**Fig. 6 – Computed visual field (pattern deviation and Bebie curve) of the right (A) and left eye (B) after the treatment, showing normal findings (patient had no fixation errors; 17% false positive errors in the right eye; 5% false positive and 5% false negative errors in the left eye).**

## Discussion

GPA is one of the ANCA-associated small-vessel vasculitides. It is clinically distinguished from other forms of systemic vasculitides due to the fact that it affects the upper and lower respiratory tracts and kidneys and by the histological presence of granulomatous inflammation. The majority of patients are Caucasian, gender distribution is equal, and the disease usually starts in the fifth decade, but it can occur at any age, including childhood. Differential diagnoses are vast, ranging from infections to other vasculitides, including Henoch-Schönlein purpura, sarcoidosis, and Behcet disease<sup>10</sup>. GPA is characterized by symptoms on the upper and lower respiratory tract and kidneys, as we described. However, unexplained constitutional symptoms like fever and weight loss are very often the initial symptoms of the disease. Ocular manifestations have been reported to occur in 30%–60% of patients with this disease<sup>5, 10</sup>. That is why a complete ophthalmological examination is an important part of the medical check-up in patients suffering from GPA. Any part of the eye may be affected. Keratitis<sup>5, 6</sup>, conjunctivitis, scleritis<sup>5, 11</sup>, nasolacrimal duct obstruction, uveitis<sup>12</sup>, orbital pseudotumor<sup>13</sup>, retinal vasculitis<sup>14</sup> and retinal vessel occlusion<sup>5</sup>, optic perineuritis (with thickening of the optic nerve in imaging scans)<sup>15–17</sup>, or compressive optic neuropathy<sup>18</sup>, have all been described. Visual loss has been reported in 8% of patients. CT or nuclear magnetic resonance imaging of the orbit and sinuses may provide important information.

We presented a unique manifestation of GPA-associated optic perineuritis in a teenage patient that was not previously reported at such a young age (all previous reports include only elderly patients in the seventh or eighth decade of life)<sup>15–17</sup>. The patient began therapy with steroids as intravenous pulse therapy and then continued with oral steroid therapy, which was slowly tapered till

discontinuance. Our patient responded to treatment with marked improvement in her vision. She tolerated a treatment regimen of 5 mg of prednisone every other day quite well, without new exacerbations, thus there was no need for using immunosuppressive agents.

In our patient, the exacerbations appeared after tapering the dose of steroids below 2.5 mg every other day. It is important to find the minimum dose for keeping the disease under control and prevent exacerbations<sup>14</sup>. Usually, the initial therapy of GPA is daily oral corticosteroid therapy. If that is not enough, pulse dose steroids in combination with immunosuppressives, or even biologic treatment, are needed<sup>9</sup>. It was shown that this treatment has been effective in inducing remission in more than 90% of patients. The mean time to reach remission was 12 months, but in some patients, two years of treatment were necessary before all symptoms have been resolved. Response to treatment is defined as a resolution of the inflammatory manifestations. However, in order to conclude that the patient is a nonresponder to a certain immunosuppressive treatment, at least several months of treatment must pass without any response. Our patient was followed up for three years after treating the optic nerve oedema. The patient is well, without any exacerbations, and she is receiving 5 mg of prednisone every other day.

## Conclusion

Visual impairment can occur as a part of underlying systemic disease such as GPA, even in the pediatric population. To our knowledge, this is the first case of optic perineuritis presented in a child. We emphasized the importance of early diagnosis and treatment of the disease, which, if untreated, can lead to permanent loss of vision. A team-work approach and a prompt response are crucial for treating patients suffering from multisystem diseases.

## REFERENCES

1. Grygiel-Górniak B, Limphaibool N, Perkowska K, Puszczewicz M. Clinical manifestations of granulomatosis with polyangiitis: key considerations and major features. *Postgrad Med* 2018; 130(7): 581–96.
2. Lamprecht P, Kerstein A, Klapa S, Schinke S, Karsten CM, Yu X, et al. Pathogenetic and clinical aspects of anti-neutrophil cytoplasmic autoantibody-associated vasculitides. *Front Immunol* 2018; 9: 680.
3. Jarivala MP, Laxer RM. Primary vasculitis in childhood: GPA and MPA in childhood. *Front Pediatr* 2018; 6(8): 226.
4. Bohm M, Gonzalez Fernandez MI, Ozgen S, Pistorio A, Dolezalova P, Brogan P, et al. Clinical features of childhood granulomatosis with polyangiitis (Wegener's granulomatosis). *Pediatr Rheumatol Online J* 2014; 12: 18.
5. Tarabishy AB, Schulte M, Papaliadis GN, Hoffman GS. Wegener's granulomatosis: Clinical manifestations, differential diagnosis, and management of ocular and systemic disease. *Surv Ophthalmol* 2010; 55(5): 429–44.
6. Rothschild PR, Pagnoux C, Seror R, Brézgin AP, Delair E, Guillemin L. Ophthalmologic Manifestations of Systemic Necrotizing Vasculitides at Diagnosis: A Retrospective Study of 1286 Patients and Review of the Literature. *Semin Arthritis Rheum* 2013; 42(5): 507–14.
7. Leavitt RY, Fauci AS, Bloch DA, Michel BA, Hunder GG, Arend WP, et al. The American College of Rheumatology 1990 criteria for the classification of Wegener's granulomatosis. *Arthritis Rheum* 1990; 33(8): 1101–7.
8. Thai LH, Charles P, Resche-Rigon M, Desseaux K, Guillemin L. Are anti-proteinase-3 ANCA a useful marker of granulomatosis with polyangiitis (Wegener's) relapses? Results of a retrospective study on 126 patients. *Autoimmun Rev* 2014; 13(3): 313–8.
9. Pagnoux C, Guillemin L. Treatment of granulomatosis with polyangiitis (Wegener's). *Expert Rev Clin Immunol* 2015; 11(3): 339–48.
10. Shafiei K, Luther E, Archie M, Gulick J, Fowler MR. Wegener granulomatosis: case report and brief literature review. *J Am Board Fam Pract* 2003; 16(6): 555–9.
11. Pakrou N, Selva D, Leibovitch I. Wegener's granulomatosis: ophthalmic manifestations and management. *Semin Arthritis Rheum* 2006; 35(5): 284–92.

12. *Kubaisi B, Abu Samra K, Foster CS.* Granulomatosis with polyangiitis (Wegener's disease): An updated review of ocular disease manifestations. *Intractable Rare Dis Res* 2016; 5(2): 61–9.
13. *Ismailova DS, Abramova JV, Novikov PI, Grusha YO.* Clinical features of different orbital manifestations of granulomatosis with polyangiitis. *Graefes Arch Clin Exp Ophthalmol* 2018; 256(9): 1751–6.
14. *Paović J, Paović P, Vukosavljević M.* Clinical and immunological features of retinal vasculitis in systemic diseases. *Vojnosanit Pregl* 2009; 66(12): 961–5.
15. *Purvin V, Kawasaki A.* Optic perineuritis secondary to Wegener's granulomatosis. *Clin Exp Ophthalmol* 2009; 37(7): 712–7.
16. *Takazawa T, Ikeda K, Nagaoka T, Hirayama T, Yamamoto T, Yanagihashi M, et al.* Wegener granulomatosis-associated optic perineuritis. *Orbit* 2014; 33(1): 13–6.
17. *Shunmugam M, Morley AM, Grabam E, D'Cruz D, O'Sullivan E, Malhotra R.* Primary Wegener's granulomatosis of the orbital apex with initial optic nerve infiltration. *Orbit* 2011; 30(1): 24–6.
18. *Aakalu VK, Ahmad AZ.* Wegener granulomatosis causing compressive optic neuropathy in a child. *Ophthalmic Plast Reconstr Surg* 2009; 25(4): 327–8.

Received on February 23, 2019.

Revised on May 12, 2019.

Accepted on May 14, 2019.

Online First May, 2019.